



**PATIENT**

Oreo Levy

**SPECIES**

Feline

**BREED**

DSH

**SEX**

Male Neutered

**AGE**

1 year

**WEIGHT**

12lbs

**INTERPRETED BY**

Maggie Machen  
Lamy, DVM  
DACVIM (Cardiology)

**IMAGING PERFORMED BY**

Pamela Harrigan,  
RDCS

**HOSPITAL NAME**

Mass Veterinary Services

**REFERRING VET**

Dr. Masloski

**INVOICE**

24113

**DATE**

5/10/22

**PRESENTING CLINICAL SIGNS**

History: Oreo has a history of chronic nasal disease. Recently noted to have a heart murmur. Having a lymph node aspirate in June. Good appetite; normal activity level. Does have some sneezing with discharge. On exam today: NSR, grade II/VI murmur parasternal murmur, PSS, lung fields clear, compressible thorax, referred upper airway noises. BP: 110, 120 mmHg. No medications. \*No sedation for study

**ECHOCARDIOGRAM FINDINGS**

2D, m-mode, color flow and Doppler imaging is available.

**Left ventricle:** The LV diameter is normal with adequate myocardial function. The LV wall thicknesses are normal. The papillary muscles are normal. The endocardium appears mildly hyperechoic.

**Left atrium:** The left atrium is normal in dimension. No obvious spontaneous contrast or thrombi seen.

**Mitral valve:** The mitral valve is normal in structure and mobility. No obvious systolic anterior motion is seen. No MR.

**Aortic valve/Aorta:** The aortic valve is normal in morphology and mobility. Normal aortic outflow velocity; laminar flow. No aortic insufficiency.

**Right ventricle:** Normal right ventricular diameter and morphology indicating no overt evidence of pulmonary arterial hypertension.

**Right atrium:** The right atrium is normal in dimension.

**Tricuspid valve:** The tricuspid valve appears normal with trivial tricuspid regurgitation.

**Pulmonic valve/Pulmonary artery:** The pulmonic valve is normal in morphology and mobility. No pulmonic insufficiency. Normal RVOT velocity; laminar flow.

**Pericardium/other:** No pericardial or pleural effusion noted. No obvious cardiac masses.

**Heart rhythm:** ECG reveals a sinus rhythm with an average HR of 200bpm.

**2-Dimensional Measurements**

Ao diam (cm)	1.1
LA diam (cm)	1.2
LA:Ao (Swe)	1.1
IVS thickness (cm)	0.4
LVID diastole (cm)	1.58
PW thickness (cm)	0.48
LVID systole (cm)	0.9
FS (%)	44

**Doppler Measurements**

PV Vmax (m/s)	1.0
AoV Vmax (m/s)	1.3
MR Vmax (m/s)	NA
TR Vmax (m/s)	NA
TR PG (mmHg)	NA

**INTERPRETATION OF THE FINDINGS**

Overtly normal cardiac structure and function. The LV wall thickness is normal and there is no evidence of elevated left atrial pressure. No cause for the murmur is identified in this study (likely due to sedation), making it likely physiologic in origin (i.e., secondary to tachycardia, volume changes, etc.).

Prognosis is open.

**RECOMMENDATIONS**

- Given these findings, no medications are indicated.
- No cardiac contraindication for general anesthesia.



**PATIENT**  
Oreo Levy

- Monitor for any clinical evidence of cardiac compromise, including respiratory changes and/or signs of a blood clot event (paralysis, neurologic changes, etc.).

**PLAN**

**SPECIES**  
Feline

- Recommend recheck echocardiogram in 1 year to reassess murmur origin and screen for development of disease the pre-existing murmur may mask.

**IMAGES**

**BREED**

DSH

**SEX**

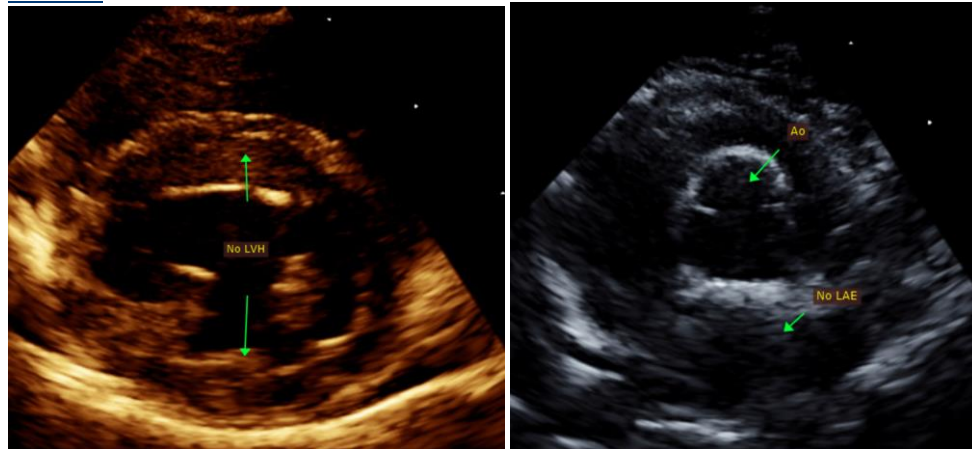
Male Neutered

**AGE**

1 year

**WEIGHT**

12lbs



The information and recommendations provided are based on the images presented by the referring veterinarian. No evaluation can be communicated regarding pathology that was not visible in the image/video clips provided.

**INTERPRETED BY**

Maggie Machen  
Lamy, DVM  
DACVIM (Cardiology)

Thank you for this referral. This report was generated using transcription software, and minor dictation errors may be present. If the clinical or image interpretation does not parallel your findings or if I can be of any further assistance please contact me.

**IMAGING PERFORMED BY**

Pamela Harrigan,  
RDCS

**Maggie Machen Lamy, DVM**  
Diplomate of the American College of Veterinary Internal Medicine (Cardiology)  
info@sonopath.com

**HOSPITAL NAME**

Mass Veterinary  
Services

Echocardiogram performed by: Pamela Harrigan, RDCS  
Pet Animal Ultrasound Service (4paus.com)

**REFERRING VET**

Dr. Masloski

**INVOICE**

24113

**DATE**

5/10/22